9 Other Papulosquamous Disorders

Bernard Cribier, Gary S. Wood and George T. Reizner

Chapter Contents

Small Plaque Parapsoriasis 164
Large Plaque Parapsoriasis 165
Pityriasis Lichenoides 165
Pityriasis Rubra Pilaris 168
Pityriasis Rosea 172
Pityriasis Rotunda 174
Granular Parakeratosis 174

SMALL PLAQUE PARAPSORIASIS

Synonyms: ■ Chronic superficial [scaly] dermatitis ■ Digitate dermatosis

Key features

- Chronic, asymptomatic, erythematous scaly patches
- Lesions are generally <5 cm in diameter or digitate
- Histologically, mild, nonspecific spongiotic dermatitis with parakeratosis is seen
- There is a predominance of $CD4^+$ T cells in the lymphocytic infiltrate
- A dominant T cell clonality is demonstrable in some cases

Introduction and History

Since the introduction of the term "parapsoriasis" by Brocq in 1902[1], there has been much confusion and debate regarding this controversial topic[2]. For example, the term "parapsoriasis en gouttes" is no longer used as it specifically refers to the entity pityriasis lichenoides. In addition, it can be difficult to clearly define the term "parapsoriasis en plaques", as the lesions vary in size from small to large and are often patches rather than plaques. Since the 1990s, many authors have proposed that *large plaque parapsoriasis* represents either the early patch stage of mycosis fungoides (MF), which has an indolent course and excellent prognosis, or is a precursor of MF[2]. Because the vast majority of patients have a benign clinical presentation and course, *small plaque parapsoriasis* is considered a separate entity[3]. Reports of patients with small plaque parapsoriasis progressing to MF are quite rare[4].

Epidemiology

Small plaque parapsoriasis is more common in middle-aged and elderly individuals, but it may also occur in children. Parapsoriasis peaks during the fifth decade of life and occurs in all racial groups and geographic regions. There is a male predominance (male : female ratio ~3 : 1).

Pathogenesis

The etiology of small plaque parapsoriasis is unknown. It is characterized by sparse lymphoid infiltrates within the superficial dermis (with variable exocytosis into the epidermis) that are composed primarily of $CD4^+$ T cells[5]. In some cases of small plaque parapsoriasis, T cell clonality has been demonstrated within the cutaneous infiltrate[5,6], and a clonal population may also be detected in the blood[7]. However, determining the significance of these findings can prove difficult. In most patients, molecular genetic studies demonstrate an oligoclonal or pseudo-monoclonal pattern[5].

Clinical Features

Despite inclusion of the word "plaque" in the terminology, small plaque parapsoriasis is a disease composed of patches with fine scales. The lesions are chronic and generally asymptomatic or mildly pruritic. They may wax and wane early on during their clinical course, but they typically become persistent and can slowly progress to become more extensive. Some cases regress fully, either spontaneously or after therapy, but this may require several months or years. Lesions can be widespread on the trunk and extremities or more limited in their distribution. In the latter instance, they often favor more sun-protected sites.

Small plaque parapsoriasis typically presents as round to oval patches that are generally <5 cm in diameter (Fig. 9.1A). They are variably erythematous (but often less intense than psoriasis) and covered with a fine scale. Some have a yellow hue, hence the historic term "xanthoerythrodermia perstans"[1]. A distinct and perhaps the most typical presentation is "digitate dermatosis", which presents as elongated, finger-like patches symmetrically distributed on the flanks[3] (Fig. 9.1B). These lesions are an exception to the 5-cm rule in that they may measure 10 cm or more along their long axis. Progression to MF is very rare, with <20 cases reported to date in the literature[4,5].

Pathology

Patches of small plaque parapsoriasis exhibit a mild, nonspecific spongiotic dermatitis with focal parakeratosis. Exocytosis of lymphocytes is variable but usually present. There are neither Pautrier microabscesses nor atypical lymphocytes, but haloed lymphocytes within the basal layer can be seen[5].

Differential Diagnosis

The diagnosis of small plaque parapsoriasis is based on clinicopathologic correlation, with other tests of minimal value. It is distinguished from large plaque parapsoriasis primarily on the basis of clinical features. The principal entities in the differential diagnosis are listed in Table 9.1.

Pityriasis rosea is distinguished from small plaque parapsoriasis by the presence of a herald patch and spontaneous resolution within a few months. Psoriasis and secondary syphilis are excluded on the basis of clinicopathologic and serologic features. Patients with pityriasis

PRINCIPAL DIFFERENTIAL DIAGNOSIS OF SMALL PLAQUE PARAPSORIASIS AND LARGE PLAQUE PARAPSORIASIS/ EARLY STAGE MYCOSIS FUNGOIDES	
Small plaque parapsoriasis	**Large plaque parapsoriasis/ early stage mycosis fungoides***
Pityriasis rosea	Drug eruption, in particular mycosis fungoides-like
Drug eruption, in particular pityriasis rosea-like	Psoriasis
Pityriasis lichenoides chronica	Poikilodermatous autoimmune connective tissue disease (e.g. dermatomyositis)
Psoriasis, including guttate	Poikilodermatous genodermatoses (see Table 63.9)
Mycosis fungoides	Chronic radiodermatitis
Secondary syphilis	
Nummular dermatitis	

*While some authors believe that large plaque parapsoriasis represents an entity distinct from mycosis fungoides (MF) or a potential precursor of MF, many authorities in the field of cutaneous lymphomas consider it to be an early manifestation of MF.

Table 9.1 Principal differential diagnosis of small plaque parapsoriasis and large plaque parapsoriasis/early stage mycosis fungoides.

Downloaded for Anonymous User (n/a) at Egyptian Knowledge Bank from ClinicalKey.com by Elsevier on March 10, 2024. For personal use only. No other uses without permission. Copyright ©2024. Elsevier Inc. All rights reserved.

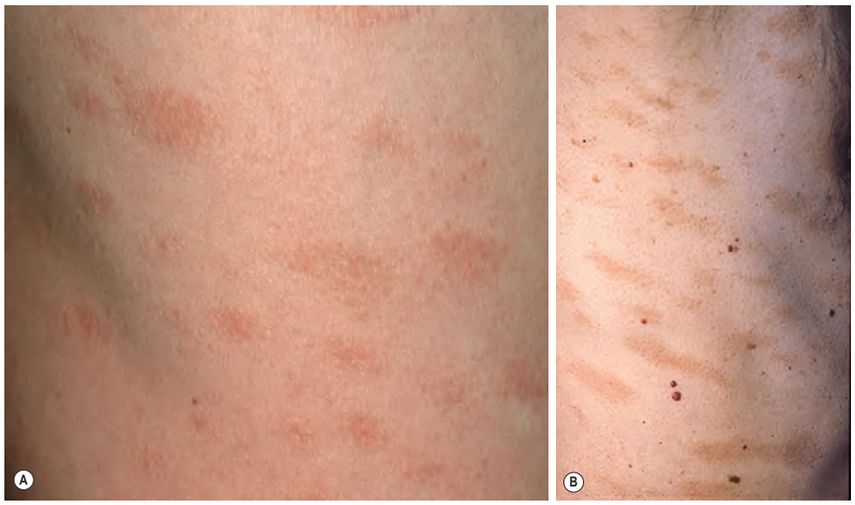

Fig. 9.1 Small plaque parapsoriasis. A Small (<5 cm), dull pink, slightly scaly patches on the trunk. **B** Digitate dermatosis with elongated finger-like lesions on the flank that are pink–brown to yellow–brown in color. *A, Courtesy Lorenzo Cerroni, MD.*

THERAPEUTIC LADDER FOR SMALL PLAQUE PARAPSORIASIS AND LARGE PLAQUE PARAPSORIASIS/ EARLY STAGE MYCOSIS FUNGOIDES	
Small plaque parapsoriasis	**Large plaque parapsoriasis/ early stage mycosis fungoides* (see Ch. 120)**
• Topical corticosteroids, mid- to high-potency (2) • Sunlight (2) • Ultraviolet B (UVB) phototherapy – broadband or narrowband (2) • PUVA (psoralen plus UVA) phototherapy (2) • UVA1 phototherapy (2) • Antihistamines†	• Topical corticosteroids, high-potency (2) • Ultraviolet B (UVB) phototherapy – broadband or narrowband (2) • PUVA (psoralen plus UVA) phototherapy (2) • UVA1 phototherapy (2) • Topical bexarotene (2) • Topical imiquimod (3) • Topical nitrogen mustard (3) • Antihistamines†
*While some authors believe that large plaque parapsoriasis represents an entity distinct from mycosis fungoides (MF) or a potential precursor of MF, many authorities in the field of cutaneous lymphomas consider it to be an early manifestation of MF. †If pruritus is present.	

Table 9.2 Therapeutic ladder for small plaque parapsoriasis and large plaque parapsoriasis/early stage mycosis fungoides. Key to evidence-based support: (1) prospective controlled trial; (2) retrospective study or large case series; (3) small case series or individual case reports.

lichenoides, acute and chronic, have lesions that are smaller and more widely distributed than do patients with small plaque parapsoriasis. Drug eruptions resembling pityriasis rosea or MF need to be considered and excluded.

Treatment

All therapeutic approaches are based primarily on uncontrolled case series, case reports, or anecdotal evidence (Table 9.2). Patients with small plaque parapsoriasis should be reassured that the risk of developing MF is extremely low. Patients may be followed without treatment if they prefer. Standard therapy includes topical corticosteroids and narrowband ultraviolet B (NB-UVB) therapy[8,9]. Clinical improvement is usually observed, but recurrences are common[9]. The role of phototherapy in terms of preventing progression to MF is uncertain[10].

LARGE PLAQUE PARAPSORIASIS

The exact nosology of large plaque parapsoriasis is still debated. While some authors believe that it represents an entity distinct from MF or a potential precursor of MF (see Ch. 120), many authorities in the field of cutaneous lymphomas consider it to be an early stage of MF. The clinical morphology (erythematous patches) and location (sun-protected sites) are similar to those of early MF, and the histopathologic features of untreated lesions can be indistinguishable from those of MF. The treatment options are the same as in early lesions of MF, and as in stage 1 A MF, a minority of patients progress to life-threatening disease and as a group they have the same survival as the general population. It should be emphasized that a diagnosis of early MF should be based on convincing clinicopathologic findings, eventually corroborated by molecular analysis of T cell receptor gene rearrangements.

PITYRIASIS LICHENOIDES

Synonyms: ▪ Pityriasis lichenoides et varioliformis acuta (PLEVA) ▪ Mucha–Habermann disease (PLEVA) ▪ Pityriasis lichenoides chronica (PLC) ▪ Guttate parapsoriasis (PLC)

Key features

- Pityriasis lichenoides et varioliformis acuta (PLEVA) and pityriasis lichenoides chronica (PLC) are two ends of a disease spectrum
- Both entities are characterized by recurrent crops of spontaneously regressing erythematous papules
- Lesions of PLEVA are crusted and occasionally vesiculopustular, whereas in PLC they are scaly
- Individual patients may show intermediate or mixed lesions
- Histologically, an interface dermatitis with necrotic keratinocytes is seen
- The infiltrate is predominantly T cells that are often monoclonal

Introduction

Pityriasis lichenoides is an uncommon disorder that encompasses pityriasis lichenoides et varioliformis acuta (PLEVA), the febrile ulceronecrotic Mucha–Habermann disease (FUMHD) variant of PLEVA, and pityriasis lichenoides chronica (PLC). These acute and chronic forms of pityriasis lichenoides exist on a disease spectrum with variable presentations that can pose diagnostic and therapeutic challenges[11,12]. They are papular, often clonal T cell disorders that may rarely be associated with MF[13].

History

The two major variants of pityriasis lichenoides – PLEVA and PLC – were described as the 19th century ended and the 20th century began[11]. Pityriasis lichenoides was included in Brocq's 1902 treatise[1] on a group of chronic, idiopathic dermatoses that he termed "parapsoriasis". Nowadays, however, it is considered a separate entity.

Downloaded for Anonymous User (n/a) at Egyptian Knowledge Bank from ClinicalKey.com by Elsevier on March 10, 2024. For personal use only. No other uses without permission. Copyright ©2024. Elsevier Inc. All rights reserved.

Epidemiology

Pityriasis lichenoides is more prevalent in the pediatric population[12], but it affects patients in all age groups, races, and geographic regions. There is a male predominance.

Pathogenesis

The etiology of pityriasis lichenoides is unknown. It has been postulated to be a response to foreign antigens such as infectious agents and drugs. There is some evidence to support PLEVA being associated with viral infections, especially varicella–zoster virus[14], and in a few reports, HIV[15], parvovirus B19[16], and Epstein–Barr virus. Additional reports have described its association with medications (e.g. estrogen–progesterone, infliximab, adalimumab, statins), radiocontrast dye, and vaccines[17,18].

Both PLEVA and PLC contain lesional T cell infiltrates, sometimes with dominant T cell clonality. The concept of pityriasis lichenoides as a T cell lymphoproliferative disorder may help to explain its occasional association with other lymphoproliferative disorders such as MF[13]. In addition, this would account for the variants of pityriasis lichenoides that have numerous $CD30^+$ cells[19] or γδ T cells[20] as well as the subgroups that have been referred to as atypical pityriasis lichenoides[21] and lymphomatoid pityriasis lichenoides[22]. Because differentiation from T cell lymphomas is sometimes difficult, patients with pityriasis lichenoides and an aberrant T cell phenotype should undergo longitudinal evaluation, with the final diagnosis based upon repeated clinicopathologic correlation, including phenotypic and molecular studies of T cell clonality[21].

Clinical Features

Pityriasis lichenoides presents as recurrent crops of spontaneously regressing erythematous to purpuric papules (Fig. 9.2). The acute form (PLEVA) and the chronic form (PLC) exist on a disease continuum. Many patients have intermediate or mixed manifestations, either serially or concurrently. In patients with PLEVA, individual lesions develop crusts, ulcers, and occasionally vesicles or pustules, which

Fig. 9.2 Clinical spectrum of pityriasis lichenoides. A–C In the acute form (PLEVA), widespread erythematous papules and papulovesicles are admixed with crusted lesions; sometimes, there can be an ulcerative component (**C**). **D** Individuals with the chronic form (PLC) develop multiple dull red–brown papules, some of which have scale and may be hypopigmented. **E** In some patients the majority of lesions are characteristic of one end of the spectrum, e.g. PLEVA, but with scattered lesions suggestive of PLC. **F** Rarely, a more severe potentially life-threatening form of PLEVA, termed febrile ulceronecrotic Mucha–Habermann disease (FUMHD), may occur *de novo* or in the setting of pre-existing PLEVA. *A, D, Courtesy Julie V. Schaffer, MD; B, Courtesy Thomas Schwarz, MD; C, F, Courtesy Lorenzo Cerroni, MD.*

Downloaded for Anonymous User (n/a) at Egyptian Knowledge Bank from ClinicalKey.com by Elsevier on March 10, 2024. For personal use only. No other uses without permission. Copyright ©2024. Elsevier Inc. All rights reserved.

may heal with varioliform scars if dermal damage is extensive. Lesions are usually asymptomatic and typically resolve within weeks. Disease manifestations are confined to the skin, except rarely, when acute lesions are associated with malaise, fever, lymphadenopathy, arthritis, and/or bacteremia. The term *febrile ulceronecrotic Mucha–Habermann disease (FUMHD)* has been used to refer to such severe variants in which large, confluent necrotic skin lesions (see Fig. 9.2F) as well as mucosal, gastrointestinal, and pulmonary involvement can be observed[23,24]. In the latter group, an associated mortality rate of up to 15% has been reported[23].

In PLC, the papules are erythematous to red–brown and scaly (see Fig. 9.2D). They pursue a more indolent course, regressing over weeks to months. When these lesions subside, there may be residual hypopigmented macules; the latter are more obvious in individuals with darker skin phototypes and may be the presenting complaint (Fig. 9.3). Pityriasis lichenoides can resolve spontaneously after weeks to months or it may pursue a chronic relapsing course, sometimes interspersed with long periods of remission. Some studies have suggested that the distribution of skin lesions is more important than their acute or chronic nature in predicting outcome[25]. The average course of disease was shorter in patients with a diffuse distribution, while those with a peripheral distribution had the longest clinical course. Compared to adults, children tend to have a more persistent course and widespread distribution of lesions[26].

Fig. 9.3 Chronic form of pityriasis lichenoides (PLC) presenting as macules of hypopigmentation. This is more common in individuals with darker skin phototypes. *Courtesy Antonio Torrelo, MD.*

Pathology

Pityriasis lichenoides exhibits a superficial perivascular interface dermatitis in all cases (Fig. 9.4). Those lesions at the acute end of the spectrum contain a denser infiltrate that may be top-heavy and wedge-shaped. There is commonly an infiltration of lymphocytes into the adnexal epithelia, both follicular and eccrine[27]. Lymphocytes predominate in the infiltrate, although neutrophils may be admixed. The epidermis shows parakeratosis and evidence of damage ranging from edema to extensive epidermal necrosis in well-developed lesions. Extravasation of erythrocytes is a frequent finding. While a perivascular lymphocytic infiltrate is a constant feature, a true lymphocytic vasculitis with fibrinoid necrosis of blood vessels is uncommon, occasionally occurring in PLEVA. All of these changes are blunted in the more chronic skin lesions, where the principal microscopic features include parakeratosis and a milder interface lymphocytic infiltrate that is accompanied by focal keratinocyte necrosis and mild erythrocyte extravasation.

Lymphoid atypia is not a standard feature of pityriasis lichenoides. What has been referred to as atypical pityriasis lichenoides was defined by conventional clinical and histologic features but with an aberrant T cell phenotype[21]. Some pathologists allow occasional atypical lymphocytes or $CD30^+$ lymphocytes[19], whereas others regard this as a sign of lymphomatoid papulosis[22]. Patients with small papules that resemble pityriasis lichenoides clinically but have Pautrier microabscesses histologically were described as having "pityriasis lichenoides-like mycosis fungoides"[28], but no patients in that series evolved into typical MF. Controversies regarding T cell lymphoproliferative disorders, however, still remain.

Differential Diagnosis

The diagnosis of pityriasis lichenoides is made by the correlation of clinical features with lesional histopathology. The principal differential diagnostic considerations for pityriasis lichenoides are listed in Table 9.3. For the more acute form (PLEVA), the primary entities in the clinical and histopathologic differential diagnosis include lymphomatoid papulosis, arthropod reactions, cutaneous small vessel vasculitis, varicella, and drug eruptions[29]. For the chronic form (PLC), the principal differential diagnosis includes guttate psoriasis, lichen planus (exanthematous), pityriasis rosea, secondary syphilis, lymphomatoid papulosis, drug eruptions, and papular dermatitis. All of these alternative diagnoses can usually be excluded on the basis of key historical, clinical, pathologic, and laboratory findings. More than one biopsy specimen, T cell immunophenotyping, and molecular studies of T cell clonality may be required to achieve clinicopathologic correlation. PCR, direct fluorescent antibody (DFA), and serologic testing as well as immunohistochemical staining are helpful in excluding varicella and syphilis.

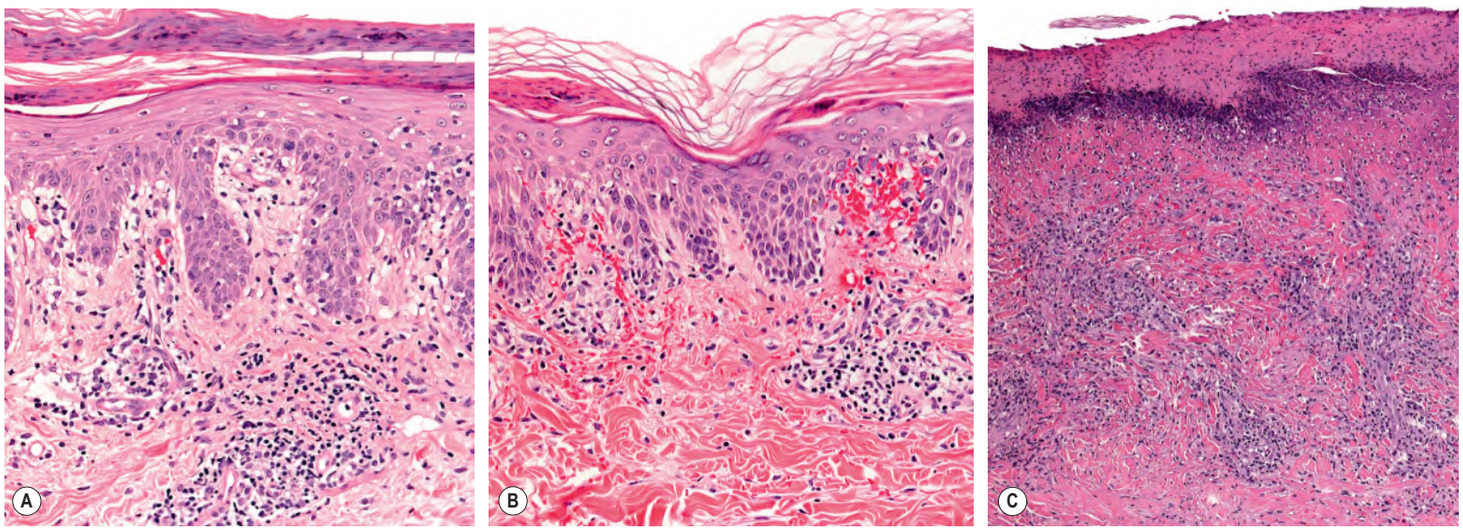

Fig. 9.4 Pityriasis lichenoides – histopathologic features. A In the chronic form (PLC), parakeratosis may be more prominent than in the acute form, but the epidermal destruction is less intense. **B** In the acute form (PLEVA), scattered necrotic keratinocytes are seen in addition to parakeratosis. The perivascular lymphoid infiltrates in the dermis are accompanied by extravasated erythrocytes, which are even present within the epidermis. As with the clinical presentations, there is a continuous histologic spectrum. **C** In the ulceronecrotic form, there is complete ulceration covered by crust. An intense lymphocytic infiltrate is seen within the dermis. *Courtesy Lorenzo Cerroni, MD.*

Downloaded for Anonymous User (n/a) at Egyptian Knowledge Bank from ClinicalKey.com by Elsevier on March 10, 2024. For personal use only. No other uses without permission. Copyright ©2024. Elsevier Inc. All rights reserved.

DIFFERENTIAL DIAGNOSIS OF PITYRIASIS LICHENOIDES	
Acute form (PLEVA)	**Chronic form (PLC)**
Lymphomatoid papulosis	Small plaque parapsoriasis
Cutaneous small vessel vasculitis	Guttate psoriasis
Varicella, enteroviral exanthems	Lichen planus (exanthematous)
Arthropod reactions	Pityriasis rosea
Erythema multiforme	Secondary syphilis
Lichenoid drug eruption	Lymphomatoid papulosis
PLEVA-like drug eruption (e.g. immune checkpoint inhibitors)	Papular dermatitis
Folliculitis	Lichenoid drug eruption
Dermatitis herpetiformis	PLC-like drug eruption (e.g. immune checkpoint inhibitors)
	When hypopigmented, extrafacial pityriasis alba

Table 9.3 Differential diagnosis of pityriasis lichenoides.

THERAPEUTIC LADDER FOR PITYRIASIS LICHENOIDES
Topical corticosteroids (2)
Topical calcineurin inhibitors (2)
Oral erythromycin (2)
Oral tetracyclines (2)
Oral azithromycin (3)
Ultraviolet B (UVB) phototherapy – broadband or narrowband (1)
PUVA (psoralen plus UVA) phototherapy (1)
Methotrexate (2)
Oral retinoids (3)
Dapsone (3)
Special treatments (3):
Antihistamines*
Systemic antibiotics†
Systemic corticosteroids‡, IVIg‡, cyclosporine‡ or TNF inhibitors‡
For recalcitrant FUMHD, JAK inhibitors or IL-6 inhibitors
*If there is pruritus.
†If there is secondary infection.
‡If there is fever, arthritis, or other systemic findings.

Table 9.4 Therapeutic ladder for pityriasis lichenoides. Key to evidence-based support: (1) prospective controlled trial; (2) retrospective study or large case series; (3) small case series or individual case reports.

Treatment

All treatments for pityriasis lichenoides are based primarily on uncontrolled case series, case reports, or anecdotes (Table 9.4)[30]. If a drug association is suspected, trial discontinuance of the suspected agent is warranted. First-line therapy includes topical corticosteroids (limited efficacy), tetracyclines, macrolide antibiotics (e.g. erythromycin, azithromycin) and various types of phototherapy (most effective; e.g. narrowband UVB)[31]. Oral antibiotics are used for their anti-inflammatory effects, with macrolides favored in younger children. A several-month course is often required, followed by a gradual taper.

More fulminant cases may require low-dose weekly methotrexate. Those rare cases associated with fever and arthritis may benefit from systemic corticosteroids, IVIg or cyclosporine, once infection has been excluded. There are also reports of the efficacy of TNF inhibitors.

PITYRIASIS RUBRA PILARIS

Synonyms: ■ Lichen ruber pilaris ■ Devergie disease ■ Lichen ruber acuminatus

Key features

- Follicular papules with an erythematous base are a characteristic finding, including on the proximal dorsal fingers
- There is a coalescence of orange–red plaques, but with obvious islands of sparing
- An orange–red waxy keratoderma of the palms and soles is often seen
- Of the six types described, the classic adult form is the most common
- The classic types (adult and juvenile) typically resolve within 3–5 years
- Type V, the atypical juvenile form, is frequently due to *CARD14* mutations
- Histologically, there is alternating ortho- and parakeratosis, both vertically and horizontally

History

Pityriasis rubra pilaris (PRP) was first described in 1835 by Claudius Tarral as a variant of psoriasis and it was given several names during the 19th century. Devergie called it "pityriasis pilaris", and later Besnier recommended the name "pityriasis rubra pilaris" in the first comprehensive illustrated article on the disease.

Epidemiology

Although PRP shows no sex bias, affecting both men and women equally, ethnic variations may exist. The incidence of this uncommon disease has two major peaks, one during the first and second decades and the second during the sixth decade[32].

Most cases are acquired, but there are familial forms, primarily autosomal dominant and less frequently autosomal recessive. The dominantly inherited form of PRP is associated with heterozygous gain-of-function mutations in *CARD14*, which encodes the caspase recruitment domain family member 14[33]. Except for the latter group of patients and those with the non-classic forms, PRP appears to be a self-limited disease process, resolving within 3 to 5 years in almost all cases.

Pathogenesis

Excluding inherited PRP due to *CARD14* mutations, infections, UV exposure, and various minor traumas to the skin have been reported to precede the onset of PRP. Autoimmunity (e.g. associated thyroid disease) or an abnormal immunologic response to particular antigens may play a role, as in patients with HIV-associated PRP (type VI). Paraneoplastic PRP has also been described in individuals with solid-organ malignancies such as renal cell, bronchogenic, and hepatocellular[34]. Rarely, drugs or vaccines have been implicated in triggering PRP, including infliximab, tyrosine kinase inhibitors (e.g. ponatinib, imatinib), and antivirals (e.g. sofosbuvir)[35].

Clinical Features

The clinical features of classic PRP are helpful in making the diagnosis. Follicular hyperkeratosis on an erythematous base is a key finding (Fig. 9.5). This results in rough papules, especially on the dorsal aspect of the proximal fingers, reminiscent of a nutmeg grater. These papules are also seen on the trunk and extremities, and they can coalesce to form large salmon-colored to orange–red plaques with distinctive "islands of sparing". The plaques can then progress to an erythrodermic appearance with varying degrees of exfoliation (see Figs. 10.7 & 10.8). The palms and soles are commonly involved with a distinctive orange–red waxy keratoderma (Fig. 9.6). Erythema with a fine diffuse scale is often seen on the scalp. Of note, scalp disease that mimics seborrheic dermatitis is a common initial clinical manifestation of adult PRP, and rapid progression to erythroderma can occur over several weeks.

Downloaded for Anonymous User (n/a) at Egyptian Knowledge Bank from ClinicalKey.com by Elsevier on March 10, 2024. For personal use only. No other uses without permission. Copyright ©2024. Elsevier Inc. All rights reserved.

Fig. 9.5 Pityriasis rubra pilaris. A Orange–red follicular papules with coalescence into large scaly plaques, in addition to islands of sparing; follicular hyperkeratosis is often easier to appreciate within the relatively spared islands. **B** On the dorsal aspects of the digits, clustered keratotic follicular papules can resemble a "nutmeg grater". **C** The islands of sparing may be sharply demarcated; note the salmon color of the plaques. Both photoaggravated and phototriggered forms of PRP exist. Patients can eventually become diffusely erythrodermic, but follicular accentuation of the scale (**D**) and small islands of sparing (**E**) can provide clues. *B, Courtesy Antonio Torrelo, MD; C, Used with permission of the Mayo Foundation for Medical Education and Research.*

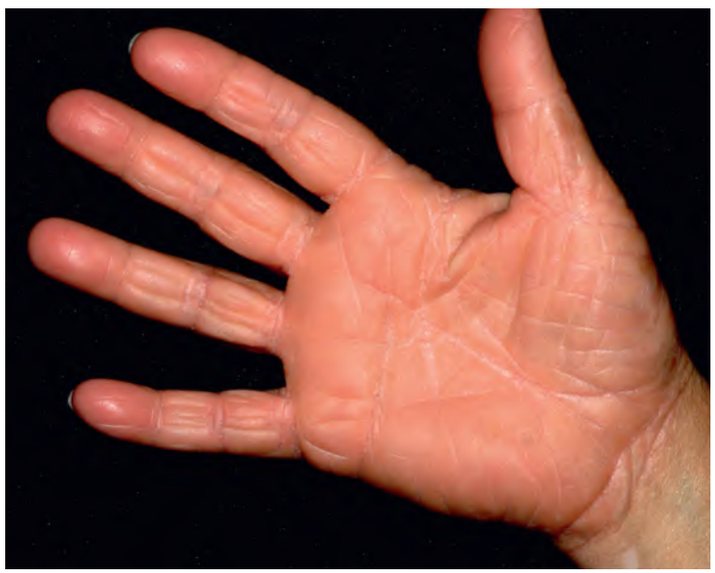

Fig. 9.6 Pityriasis rubra pilaris. The orange–red color of the skin, including that of the palmar keratoderma, aids in the clinical diagnosis. *Courtesy Luis Requena, MD.*

Nail involvement is characterized by a thickened plate with a yellow–brown discoloration and subungual debris. The mucous membranes are rarely involved, but they may show features similar to oral lichen planus.

The most common form of PRP (type I) usually begins in the head and neck region and then progressively advances caudally. Pruritus and burning have been reported in 20% of patients with PRP. Although less common than in atopic dermatitis or Darier disease, Kaposi varicelliform eruption can occur in patients with PRP. As with other forms of erythroderma (see Ch. 10), eruptive seborrheic keratoses may appear. Both photoaggravated and phototriggered forms of PRP can also occur (see Fig. 9.5C). Resolving PRP may have a clinical appearance that resembles erythema gyratum repens (see Fig. 19.9).

The classification of the different forms of PRP is based upon age, duration, and type of cutaneous involvement (Fig. 9.7)[36]. Type I (classic adult) PRP is the most common form and is typically self-limited, clearing within 3 years in 80% of patients. Type II differs from type I by a palmoplantar keratoderma with a coarse and lamellated scale, a more ichthyosiform scaling on the lower extremities, occasional alopecia, and a protracted clinical course.

PRP types III–V are seen in children and adolescents. Type III, the classic juvenile form, closely resembles the classic adult form and

Downloaded for Anonymous User (n/a) at Egyptian Knowledge Bank from ClinicalKey.com by Elsevier on March 10, 2024. For personal use only. No other uses without permission. Copyright ©2024. Elsevier Inc. All rights reserved.

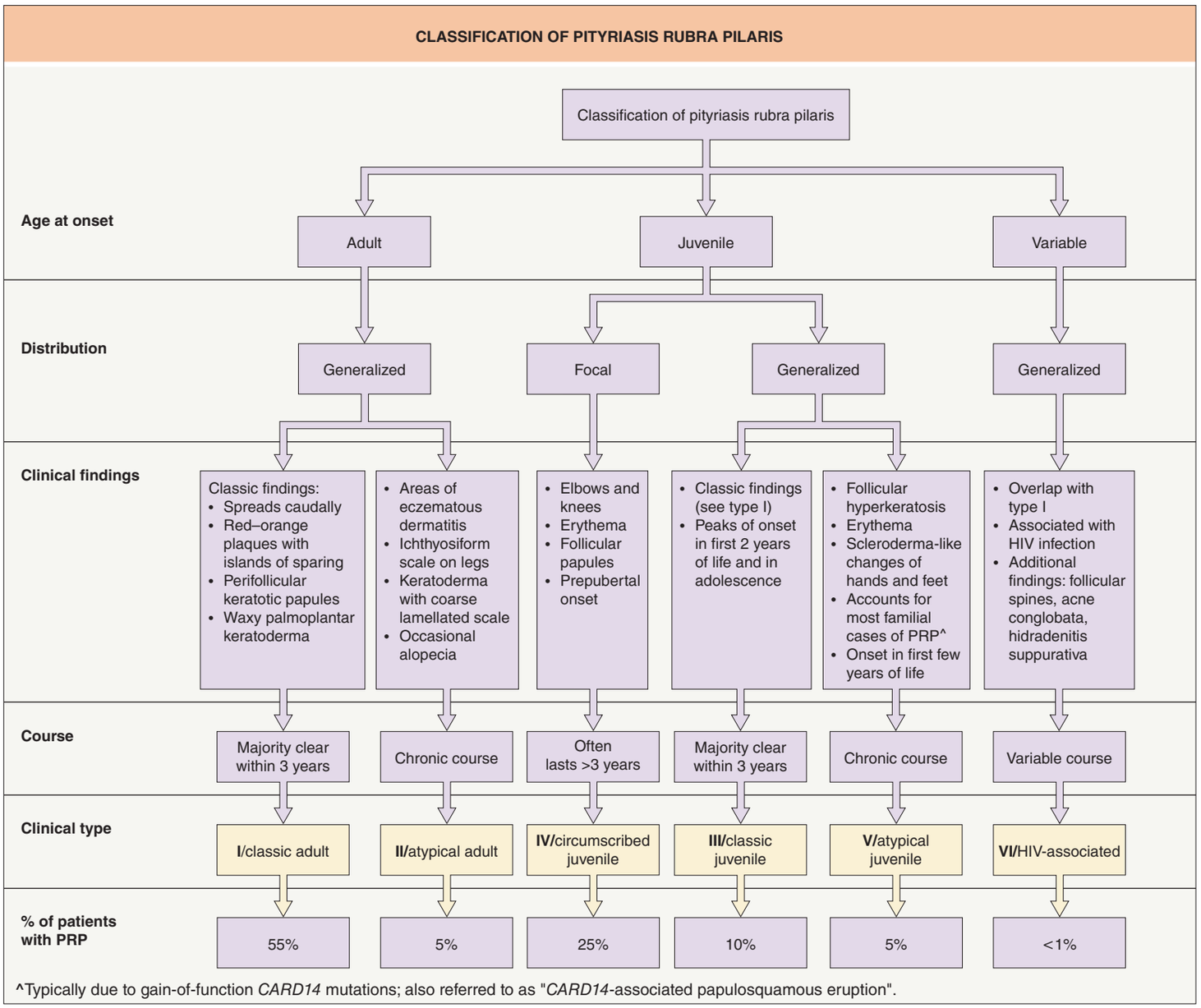

Fig. 9.7 Classification of pityriasis rubra pilaris (PRP). Type VI PRP is also referred to as HIV-associated follicular syndrome.

also typically clears within 3 years. Type IV (circumscribed) is the most common of the juvenile forms, and its focal nature sets it apart from the other clinical presentations (Fig. 9.8). Type V, the atypical juvenile form, is frequently due to *CARD14* mutations; it has features similar to type II but with more ichthyosiform scaling and a chronic course (see Fig. 8.9). Patients with *CARD14* mutations tend to present with clinical features observed in both PRP (often resembling type V PRP but sometimes with classic "islands of sparing") and psoriasis. These patients have been referred to as having "*CARD14*-associated papulosquamous eruption (CAPE)". In addition to a family history of PRP or psoriasis, characteristic features of CAPE include an early age of onset; prominent involvement of the cheeks, chin, and ears; involvement of the palms and soles; and a chronic course with a variable response to conventional treatments[33]. Gain-of-function *CARD14* mutations have rarely been detected in other types of PRP[37].

PRP type VI is associated with HIV infection, and while it often fails to respond to conventional therapy for PRP, it may improve with antiretroviral therapy. These patients can have erythematous follicular papules and keratotic spines as well as nodulocystic lesions of acne conglobata and hidradenitis suppurativa. In addition, coalescence of inflammatory plaques into an erythroderma may occur, as in PRP type I.

Pathology

Psoriasiform dermatitis with irregular hyperkeratosis and alternating vertical and horizontal ortho- and parakeratosis ("checkerboard pattern") is distinctive (Fig. 9.9A). The hair follicles are dilated and filled with a keratinous plug, while the "shoulder" of stratum corneum surrounding the follicular opening frequently shows parakeratosis (Fig. 9.9B). The interfollicular epidermis often exhibits hypergranulosis as well as thick, shortened rete pegs. A sparse lymphohistiocytic perivascular infiltrate is seen in the underlying dermis. Acantholysis and focal acantholytic dyskeratosis within the epidermis have also been described and can be helpful in distinguishing PRP from psoriasis. In CAPE, histopathologic features are more similar to PRP than to psoriasis, including alternating checkerboard parakeratosis and orthokeratosis and follicular plugging[38].

Differential Diagnosis

The major entity in the differential diagnosis is psoriasis. The distinctive orange–red palmoplantar keratoderma plus the keratotic follicular papules with a nutmeg grater appearance, the classic islands of sparing of the trunk, and a finer scale (see Fig. 10.7), help differentiate PRP from psoriasis. The presence of oil-drop changes, small pits, and marginal

Downloaded for Anonymous User (n/a) at Egyptian Knowledge Bank from ClinicalKey.com by Elsevier on March 10, 2024. For personal use only. No other uses without permission. Copyright ©2024. Elsevier Inc. All rights reserved.

onycholysis of the nails favor psoriasis. Microscopically, acantholysis and focal acantholytic dyskeratosis, if present, are especially useful in diagnosing PRP rather than psoriasis. A thickened granular cell layer, short thicker rete pegs, limited vascular dilation in the dermal papillae, and the absence of both neutrophilic migration towards the epidermis and Munro microabscesses further help distinguish PRP from psoriasis. Histopathologic features of PRP may be seen in patients with what has been described as facial discoid dermatosis.

Early PRP of the scalp can mimic seborrheic dermatitis. The relative recalcitrant nature of scalp PRP may serve as a clue to the diagnosis. A PRP-like eruption can be seen in patients with dermatomyositis (Wong type) and cutaneous T cell lymphoma, as can erythema and scaling of the scalp. Children with acute-onset PRP may be misdiagnosed as having Kawasaki disease, and, occasionally, PRP is confused with erythrokeratodermia variabilis et progressiva or ichthyosis with confetti.

Keratotic follicular papules are also seen in keratosis pilaris and lichen spinulosus, but the lesions are more limited in scope and the other manifestations of PRP are absent. The various disorders that can present as an erythroderma are discussed in Chapter 10.

Fig. 9.8 Circumscribed juvenile pityriasis rubra pilaris (type IV). Symmetric pink plaques with scale are present on the dorsal aspect of the fingers, metacarpophalangeal joints, and knees. There are follicular keratotic papules on the knees. *Courtesy Antonio Torrelo, MD.*

Treatment

Therapy for PRP is primarily empiric, based upon case series and case reports, and often involves a combination of topical and systemic therapies. *Topical therapies* alone are typically insufficient for most patients with PRP, unless there is limited disease. Topical high-potency corticosteroids, tar, calcipotriene (calcipotriol), keratolytics (e.g. urea, salicyclic acid), and retinoids (e.g. tazarotene, tretinoin) can be used as adjuncts to systemic therapy.

Systemic retinoids represent a first-line treatment for PRP in both adults and children; an excellent response is seen in >40% of patients[39]. Isotretinoin (0.5 to 1 mg/kg/day) and acitretin (0.5 mg/kg/day) are the two most commonly prescribed retinoids, with scattered reports of some efficacy with alitretinoin. There are reports of the occasional use of higher doses of isotretinoin, but in the opinion of the authors, this is not recommended. Significant clearing is usually seen within 3–6 months of instituting therapy.

Methotrexate (5–25 mg/week) is considered second-line therapy for PRP, in particular for patients who have failed or cannot tolerate systemic retinoids. A response rate of >90% and complete clearance in ~40% of patients has been observed[40]. As with retinoids, clinical responses are usually seen within 3–6 months. Hepatotoxicity and myelosuppression are well-known potential side effects (see Ch. 130).

In severe cases of PRP, a combination of methotrexate (5–25 mg/week) plus a systemic retinoid (acitretin) has been utilized. Both agents can be given at the onset of therapy, or the second medication can be added if the response to the first is inadequate. In this situation, an increased risk for hepatotoxicity must be kept in mind.

Based upon case reports and small case series, TNF inhibitors (e.g. etanercept, infliximab, adalimumab), secukinumab, and ustekinumab have led to improvement of PRP[41]. A marked to complete response was noted in 50%–80% of patients. In a small series of patients, ixekizumab was reported to be moderately successful[42]. Ustekinumab, often at higher doses, has been reported as beneficial in patients with CAPE. Due to limited data as well as the natural history of PRP, precise efficacy is difficult to assess.

Other anecdotal potential therapies include systemic immunosuppressives (e.g. azathioprine, prednisone, cyclosporine), apremilast, and IVIg, with variable results observed. Although UV light therapy runs the risk of exacerbating the disease, there are some reports of success with narrowband UVB, UVA1, or PUVA in combination with an oral retinoid[36,43].

Less toxic regimens are recommended for the classic juvenile form of PRP, given the high likelihood of spontaneous remission and the potential long-term effects of aggressive systemic therapies.

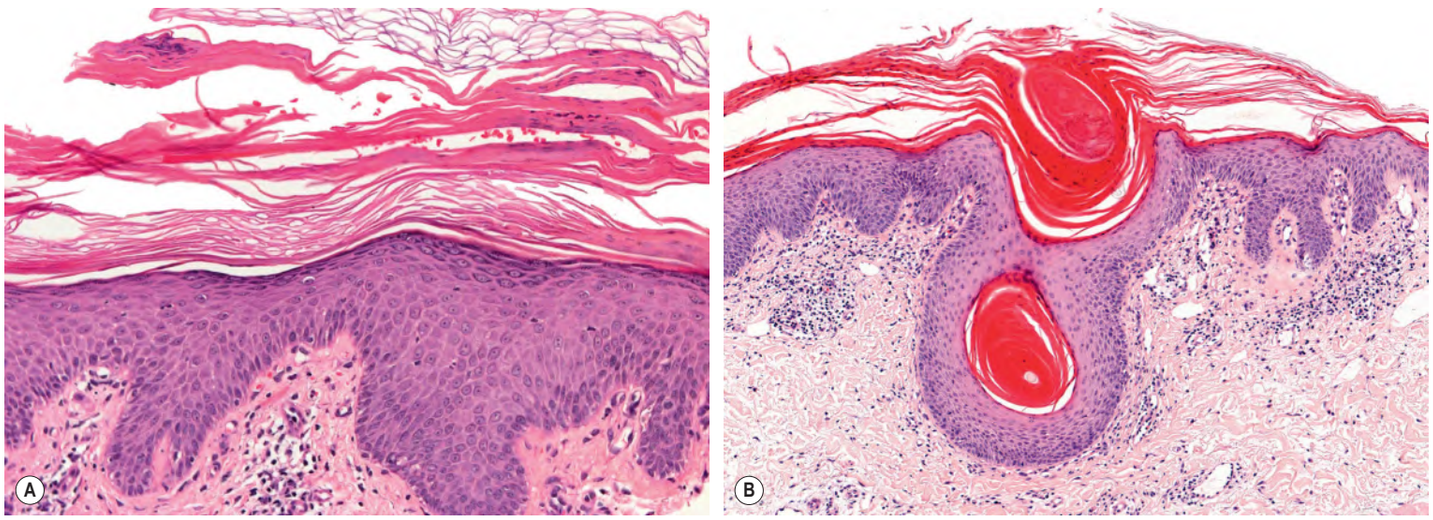

Fig. 9.9 Pityriasis rubra pilaris – histopathologic features. Psoriasiform dermatitis with alternating vertical and horizontal ortho- and parakeratosis ("checkerboard pattern") (**A**), as well as follicular hyperkeratosis with parakeratosis in the shoulders of the follicular plug (**B**). *Courtesy Lorenzo Cerroni, MD.*

Downloaded for Anonymous User (n/a) at Egyptian Knowledge Bank from ClinicalKey.com by Elsevier on March 10, 2024. For personal use only. No other uses without permission. Copyright ©2024. Elsevier Inc. All rights reserved.

PITYRIASIS ROSEA

Synonym: ■ Pityriasis rosea Gibert

Key features

- A self-limited papulosquamous eruption that is occasionally pruritic
- Seen primarily in adolescents and young adults, favoring the trunk and proximal extremities
- Herald patch followed by lesions that are usually oval in shape and oriented with their long axes along Langer cleavage lines
- Less common variants include inverse, vesicular, purpuric, and pustular

Introduction

Pityriasis rosea is a common, "acute", self-limited papulosquamous eruption that favors otherwise healthy adolescents and young adults. Its striking appearance often prompts a request for medical evaluation. There is an absence of significant systemic manifestations, and its spontaneous resolution provides great consolation to the patient. Although the classic presentation is readily recognized, atypical forms may present a greater challenge. A viral etiology has been postulated, but this remains unproven.

History

Robert Willan described "roseola annulata" in 1798 as a self-limited eruption in otherwise healthy children. In 1860, the French physician Camille Melchior Gibert first named the condition pityriasis (scaly) rosea (pink). This aptly conveyed the clinical features and remains the name that is still used today.

Epidemiology

Most cases of pityriasis rosea occur in young healthy persons, the majority of whom are between the ages of 10 and 35 years[44]. Its peak incidence is during adolescence, and it is rarely diagnosed before the age of 2 years. There is no racial predilection and it is found worldwide. There may be a slight female predominance. The typical eruption lasts 6 to 8 weeks, though exceptionally it can persist for 5 months or longer. Some authors report a modest seasonal variation with peaks in the spring and fall or in some countries during the rainy season.

Pathogenesis

The precise cause of pityriasis rosea remains elusive, and although a viral etiology is frequently proposed, this remains controversial[45]. While attention has focused on human herpesvirus-7 (HHV-7) and, less so, on HHV-6, some studies have shown no difference in the prevalence of DNA from HHV-6 or HHV-7 in peripheral blood mononuclear cells of patients with pityriasis rosea. An association with HHV-8, H1N1 influenza virus, and SARS-CoV-2 has also been reported[46]. Proponents of a viral etiology point to the prodromal symptoms experienced by some patients, the clustering of cases, and the rarity of recurrent episodes, suggesting an immunologic defense against an infectious agent. Pityriasis rosea is considered a prototypic paraviral exanthem, i.e. a characteristic skin disease associated with a possible viral infection or reactivation, but without virus identified in the cutaneous lesions[47,48].

Clinical Features

Although classic pityriasis rosea is usually easily recognized, the more unusual variants can be more challenging to diagnose[49]. In the classic presentation, a solitary lesion appears on the trunk and enlarges over several days (Fig. 9.10)[49,50]. Less often, this initial lesion is seen on the neck or proximal extremities. It predates the remainder of the eruption by hours to days and is referred to as the "herald patch" because it heralds the onset of the disease. Its incidence varies, but in most series it has been seen in over 50% of cases. Multiple herald patches have also been reported.

The herald patch is a pink- to salmon- to pink–brown-colored patch or plaque with a slightly raised advancing margin (Fig. 9.11). The size commonly varies from 2 to 4 cm, but it can be as small as 1 cm or as large as 10 cm. The center shows the characteristic small fine scales

Fig. 9.10 Pityriasis rosea with a herald patch on the left breast. Numerous symmetrically distributed pink papules on the trunk that are round or oval in shape; associated scale is most obvious on the neck and breasts. Fewer lesions are noted on the flexor surfaces of the arms.

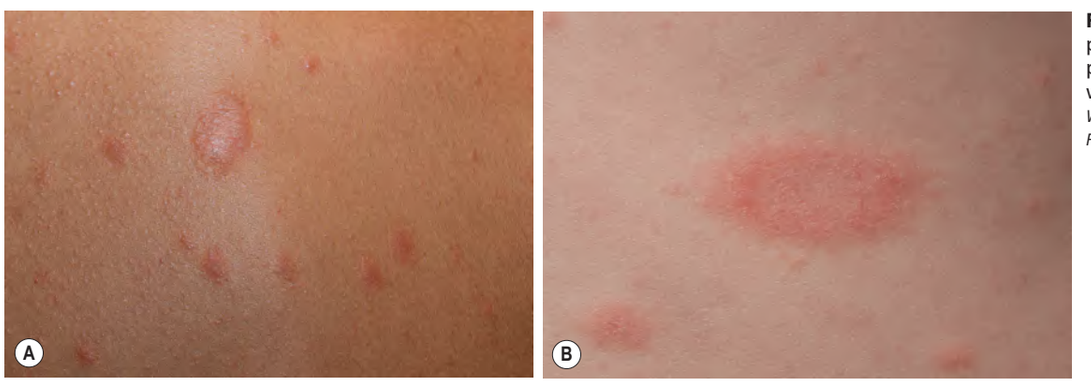

Fig. 9.11 Pityriasis rosea. A, B Herald patches in two patients with different skin phototypes. Either central or peripheral white scale can be seen. *A, Courtesy Kalman Watsky, MD; B, Used with permission of the Mayo Foundation for Medical Education and Research.*

Downloaded for Anonymous User (n/a) at Egyptian Knowledge Bank from ClinicalKey.com by Elsevier on March 10, 2024. For personal use only. No other uses without permission. Copyright ©2024. Elsevier Inc. All rights reserved.

of pityriasis rosea, and the margin has a larger, more obvious trailing collarette of scale with the free edge pointing inwards. There may be a mild prodrome with headache, fever, arthralgias, or general malaise. On occasion, the herald patch appears simultaneously with the more widespread eruption.

Typically, within the next few days, there is a blossoming of lesions on the trunk and proximal extremities. These numerous smaller thin papules and plaques are reminiscent of the larger herald patch that predated them; in more darkly pigmented skin, the lesions tend to be more papular, folliculocentric, and hyperpigmented (Fig. 9.12). Again, there is a subtle advancing border, central fine scaling, and the characteristic collarette of scale (Fig. 9.13A,B). The lesions are usually round to oval in shape, with their long axis following Langer cleavage lines (Fig. 9.13C). On the posterior trunk, such an orientation leads to what is often referred to as a "fir tree" or "Christmas tree" pattern. Minute pustules can also be seen during this initial phase of pityriasis rosea.

Fig. 9.12 Follicular accentuation of pityriasis rosea in darkly pigmented skin. Note the central hyperpigmentation and the small follicular papules. *Courtesy Aisha Sethi, MD.*

The face, palms, and soles are usually (but not always) spared. When all these features are present, the diagnosis is easiest to establish.

The eruption of pityriasis rosea usually persists for 6–8 weeks and then spontaneously resolves; however, occasional patients have lesions that may last 5 months or longer[49]. In the latter situation, the possibility of pityriasis lichenoides chronica arises. Most patients with pityriasis rosea experience few symptoms, but in some individuals, pruritus is noted that is mild to severe.

Atypical forms of pityriasis rosea require a more astute observer. Inverse pityriasis rosea involves the axillae and inguinal areas (see Fig. 9.13B) and sometimes the face. It is more common in younger children and in those with darker skin phototypes. Oral lesions are also uncommon, but they may be underreported and palmoplantar involvement is unusual. Urticarial, erythema multiforme-like, vesicular, pustular, and purpuric variants have also been described.

Pathology

The microscopic features of pityriasis rosea include spongiotic dermatitis, along with elongation of the rete ridges and enlargement of the dermal papillae. Small mounds of parakeratosis and a predominantly papillary dermal infiltrate comprised of lymphocytes and histiocytes are also common features (Fig. 9.13D). There may be mild erythrocyte extravasation with scattered intraepidermal erythrocytes. In severe cases, these features are more pronounced, including the rare formation of intraepidermal pustules.

Most patients with pityriasis rosea do not have biopsies performed, because the clinical picture is quite characteristic.

Differential Diagnosis

Pityriasis rosea can sometimes be difficult to distinguish from secondary syphilis. The presence of cutaneous signs such as split papules and condyloma lata points to syphilis, as does the history or presence of a primary chancre. Patients with secondary syphilis usually have more systemic complaints, and they often have peripheral lymphadenopathy. Histologically, the absence of plasma cells favors pityriasis rosea and immunohistochemical staining for spirochetal antigens can also be done (see Ch. 0). Serologic testing allows the diagnosis of secondary syphilis to be confirmed.

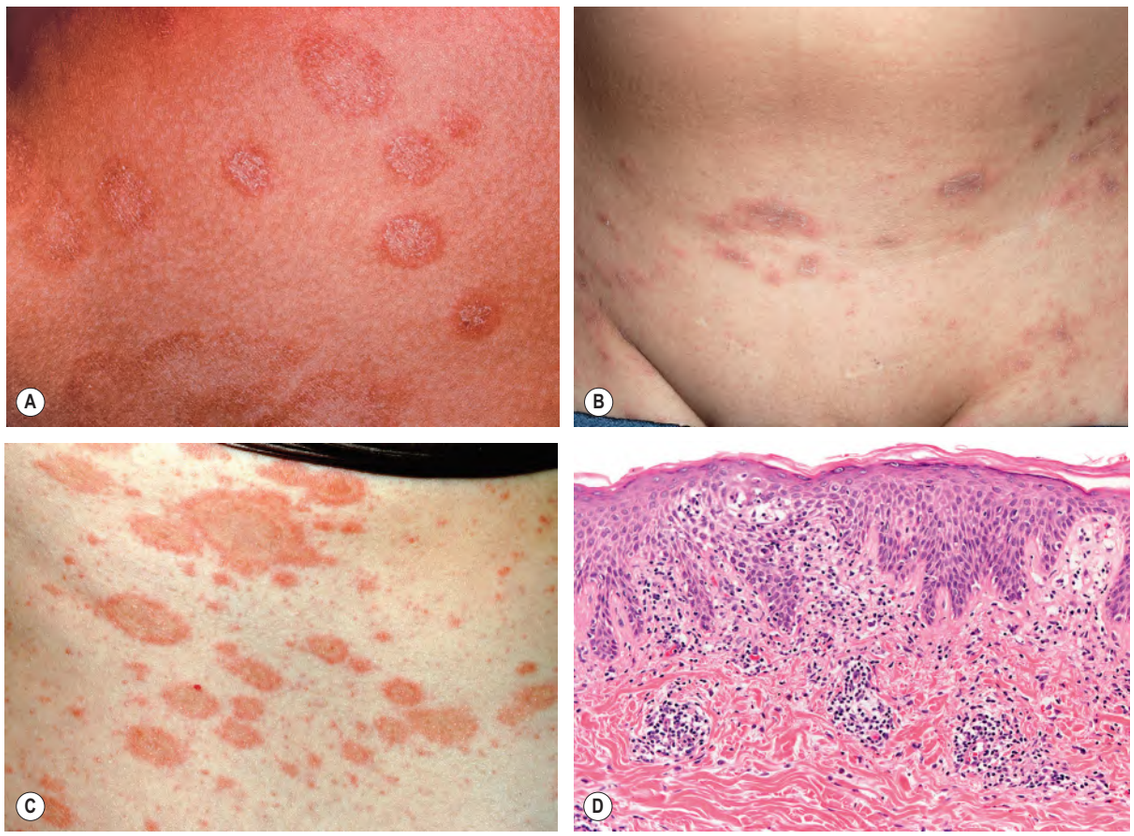

Fig. 9.13 Pityriasis rosea. A Both oval and round plaques can be seen as well as central fine scale. **B** A collarette of scale can also be seen and when lesions are limited to the pelvic region and/or axillae, the pattern of involvement is termed *inverse*. **C** A more inflammatory border may be seen and the long axes of the oval plaques follow skin cleavage lines. **D** Histopathologically, parakeratosis, mild spongiosis associated with exocytosis of lymphocytes into the epidermis, perivascular dermal lymphocytic infiltrates, and extravasated red blood cells are seen. *B, Courtesy Luis Requena, MD; C, Courtesy Julie V. Schaffer, MD; D, Courtesy Lorenzo Cerroni, MD.*

Downloaded for Anonymous User (n/a) at Egyptian Knowledge Bank from ClinicalKey.com by Elsevier on March 10, 2024. For personal use only. No other uses without permission. Copyright ©2024. Elsevier Inc. All rights reserved.

There are drug eruptions that can mimic pityriasis rosea; they have been reported in patients receiving angiotensin-converting enzyme (ACE) inhibitors, β-blockers, metronidazole, and isotretinoin, as well as arsenic, bismuth, gold, barbiturates, clonidine, hydrochlorothiazide, imatinib, omeprazole, terbinafine, TNF inhibitors, NSAIDs, and multiple vaccines[51]. A drug-induced pityriasis rosea-like eruption is often slower to resolve than the idiopathic form.

The herald patch or generalized eruption can resemble tinea corporis, tinea versicolor, or nummular dermatitis. The presence of the collarette of scale, the orientation of the lesions, and the history can help distinguish pityriasis rosea from nummular dermatitis. Guttate psoriasis usually has a thicker scale, smaller size, and lacks the fir-tree distribution. Other papulosquamous disorders such as pityriasis lichenoides should also be considered, especially when lesions last longer than 4 months.

Treatment

Because pityriasis rosea is often asymptomatic and self-limited, patient education and reassurance represent a satisfactory treatment plan. In patients with pruritus, counterirritant antipruritic lotions or low- to medium-strength topical corticosteroids may be needed for symptomatic relief. In more severe cases, UVB phototherapy (broadband or narrowband) or natural sunlight exposure and oral antihistamines can be used[52]. Rarely, a brief course of systemic corticosteroids may be required. In a 2019 Cochrane review, oral acyclovir was found to lead to "good or excellent" improvement of lesions with inconclusive effect on pruritus and oral erythromycin was shown to decrease pruritus[53]. However, a pathogenetic explanation for these findings is not clear.

Lastly, in pregnant women, there is a possible association between the development of pityriasis rosea and spontaneous abortion when there is active HHV-6 infection, in particular during the first 15 weeks of gestation[54].

PITYRIASIS ROTUNDA

Synonyms: ▪ Tinea circinata ▪ Pityriasis circinata

Key features

- Asymptomatic dermatosis seen primarily in the Far East and Mediterranean basin and in individuals of African descent
- There are large circular and polycyclic scaly patches with sharp margins that are typically hyperpigmented > hypopigmented and localized to the trunk and proximal extremities
- Histologic features are similar to those of ichthyosis vulgaris

Introduction

Pityriasis rotunda is an unusual dermatosis that can occur alone or in association with a number of unrelated conditions. There are familial cases that may represent a minor acquired ichthyosis.

History

Pityriasis rotunda was first described by Toyama in 1906 as "tinea circinata" and was later named pityriasis rotunda by Matsura.

Epidemiology

Pityriasis rotunda is most commonly observed in adults in their 30s and in children and has a slight female predominance[55,56]. It has been described in the Far East (Japan and China), the Mediterranean basin (Morocco, Italy, and Israel), and in Africans, African-Americans, and Afro-Caribbeans.

Pathogenesis

No clear unifying cause has been identified. In adults, possible associations include malnutrition, mycobacterial diseases (tuberculosis and leprosy), malignancies (e.g. hepatocellular carcinoma, gastric carcinoma, multiple myeloma), and hepatic cirrhosis[57]. However, the majority of patients, especially children, are in good health[58]. An absence of profilaggrin N-terminal domain and decreased expression of filaggrin-2 have been observed in some patients[59].

Fig. 9.14 Pityriasis rotunda. Circular, well demarcated, thin plaque with scale.
Courtesy Richard M. Haber, MD.

Clinical Features

Pityriasis rotunda is typically asymptomatic and is characterized by large circular and polycyclic lesions that are often 10 cm (but may be up to 30 cm) in diameter (Fig. 9.14). They have associated fine scale and are moderately hyperpigmented with a sharp margin and no inflammation. The trunk and extremities are favored. A hypopigmented halo has been described in some patients, and sometimes the entire lesion can be hypopigmented.

Grimalt proposed categorizing pityriasis rotunda into two groups[60]. Type I is seen primarily in Black and Asian individuals as hyperpigmented lesions, possibly in association with malnutrition or internal malignancy but with no family history. Type II occurs in younger White individuals with numerous (>30) lesions who sometimes have a family history, but no associated diseases.

Pathology

Pityriasis rotunda has microscopic features of ichthyosis vulgaris, i.e. an absent or diminished granular cell layer and moderate hyperkeratosis without parakeratosis[59]. Increased pigmentation of the basal cell layer, pigment incontinence, a perivascular lymphohistiocytic infiltrate, and follicular plugging may also be observed. Special stains for fungi are negative.

Differential Diagnosis

The differential diagnosis includes tinea corporis, tinea versicolor, leprosy, and MF. The combination of fungal culture and routine histology excludes major entities in the differential diagnosis. The hypopigmented variant of pityriasis rotunda can resemble one variant of progressive macular hypomelanosis, which has no associated scale and lacks the histologic features of ichthyosis vulgaris.

Treatment

Pityriasis rotunda is relatively difficult to treat. Trials with topical lactic acid, urea, tars, emollients, and corticosteroids have provided little benefit. Topical tretinoin cream can result in modest improvement and systemic retinoids warrant consideration for patients with more extensive disease. Spontaneous remission is possible[55].

GRANULAR PARAKERATOSIS

Synonyms: ▪ Axillary granular parakeratosis ▪ Intertriginous granular parakeratosis

Downloaded for Anonymous User (n/a) at Egyptian Knowledge Bank from ClinicalKey.com by Elsevier on March 10, 2024. For personal use only. No other uses without permission. Copyright ©2024. Elsevier Inc. All rights reserved.

Key features

- Brownish-red keratotic papules that can coalesce into plaques
- Adult form occurs more often in women and favors the axillae over other intertriginous areas
- Infantile form is associated with diaper wearing or chemical irritation (e.g. use of benzalkonium chloride) and presents as bilateral inguinal plaques or erythematous geometric plaques underneath diaper pressure points
- Histopathology is distinct, with retention of basophilic keratohyaline granules within areas of parakeratosis in the stratum corneum
- A defect in processing profilaggrin to filaggrin is a proposed mechanism

Introduction

Granular parakeratosis is an acquired, typically pruritic disorder of the axillae and other intertriginous sites, e.g. the groin and inframammary and abdominal folds. It has distinct histopathologic findings, suggesting a disorder in keratinization[61].

History

Northcutt and colleagues[61] first described granular parakeratosis in 1991. Multiple cases have been described since then in various clinical settings, suggesting a multifactorial reactive condition[62].

Epidemiology

Granular parakeratosis is observed most commonly in middle-aged women[62]. Although it is less common in young adults, there are reports in infants and children linked to diaper-wearing and exposure to benzalkonium chloride in laundry rinse aids[63]. Granular parakeratosis has been observed in all skin phototypes.

Pathogenesis

Granular parakeratosis is an acquired keratotic dermatosis originally linked to maceration and the use of various personal hygiene products, such as deodorants and antiperspirants. More recently, occlusion from diapers or chemical irritation from benzalkonium chloride (see above) has been implicated[63].

A disorder of keratinization characterized by a basic defect in the processing of profilaggrin to filaggrin has also been proposed, based upon ultrastructural and immunohistochemical studies, i.e. retention of keratohyalin granules within the stratum corneum due to a defect in filaggrin metabolism[64]. This suggests a distinctive reactive pattern rather than a specific entity[65].

Clinical Features

The primary lesions are keratotic, brownish-red papules that can have a conical shape. They may coalesce into larger, well-demarcated plaques with various degrees of maceration secondary to local occlusion (Fig. 9.15). Lesions can persist for months or longer and recur. Pruritus is the most common complaint, but irritation is also a problem if there are erosions or fissures. Some patients experience a flare with an increase in ambient temperature and sweating. The axilla is the most common site of involvement, followed in frequency by other major body folds (e.g. inguinal, inframammary). Occasionally granular parakeratosis develops in the genital area[66].

In infants, bilateral plaques within the inguinal folds or erythematous geometric plaques underlying pressure points from the diaper can be seen. Larger lesions in other intertriginous sites have been observed in older children[63].

Pathology

The characteristic feature is an unusual form of parakeratosis. The stratum corneum is thickened and compacted with increased eosinophilic staining (Fig. 9.16). Retained nuclei are present throughout this keratin layer, creating parakeratosis. The most unusual feature is the visible retention of basophilic keratohyalin granules within these areas of parakeratosis[61,64]. Because clinically similar lesions may not have these characteristic histologic features, the encompassing term "hyperkeratotic flexural erythema" has been proposed[65].

Fig. 9.15 Granular parakeratosis involving the axilla. Coalescing brown papules with hyperkeratosis and slight maceration. *Courtesy Kalman Watsky, MD.*

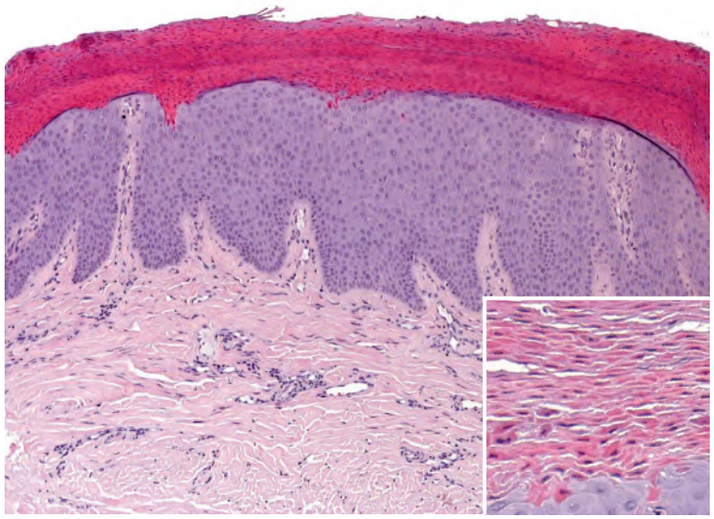

Fig. 9.16 Axillary granular parakeratosis – histopathologic findings. Marked, compact parakeratosis with small bluish granules within the stratum corneum representing keratohyaline granules (inset). *Courtesy Lorenzo Cerroni, MD.*

Differential Diagnosis

The differential diagnosis includes the most common causes of intertrigo (e.g. seborrheic dermatitis, candidiasis, inverse psoriasis, erythrasma) as well as Hailey–Hailey disease, Darier disease, and pemphigus vegetans. Irritant or allergic contact dermatitis also needs to be considered in some patients. A biopsy will confirm the diagnosis of granular parakeratosis.

Treatment

Based upon case reports and small series, therapeutic success has been reported with topical corticosteroids, vitamin D analogues, retinoids, ammonium lactate, and antifungals. In addition, cryotherapy, laser therapy[67], and oral isotretinoin or antibiotics have been used[65]. Spontaneous resolution has also been observed (including in infants), as have relapses.

Additional figures available in our eBook (see inside front cover for access code).

Downloaded for Anonymous User (n/a) at Egyptian Knowledge Bank from ClinicalKey.com by Elsevier on March 10, 2024. For personal use only. No other uses without permission. Copyright ©2024. Elsevier Inc. All rights reserved.

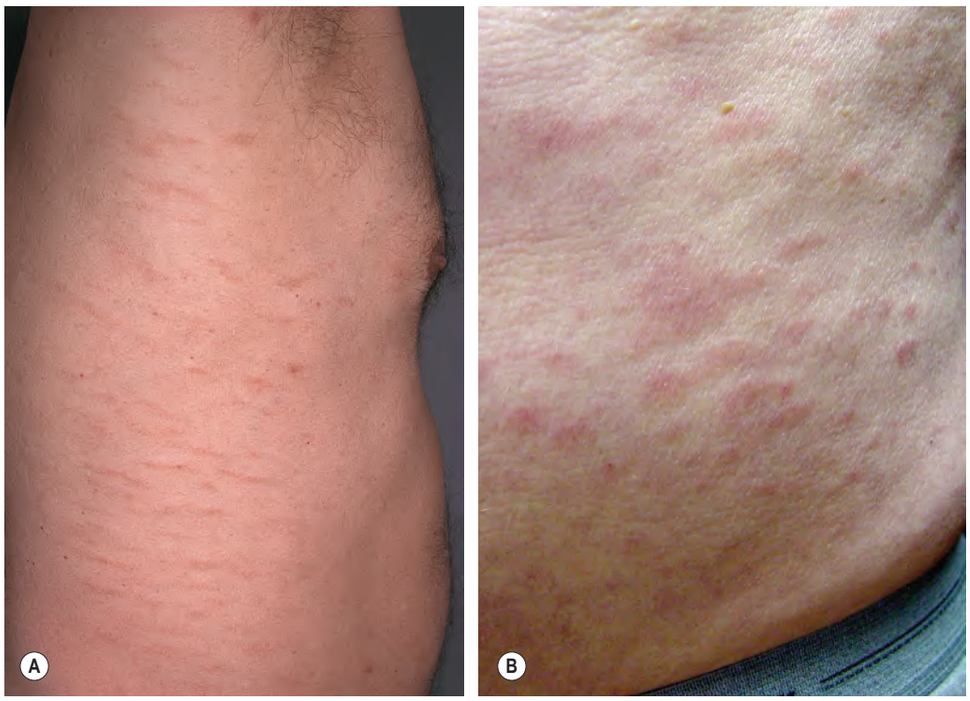

eFig. 9.1 Small plaque parapsoriasis – digitate dermatosis. A, B Elongated finger-like lesions on the flank, admixed with smaller papules in **B.** *B, Courtesy Jeffrey P. Callen, MD*.

eFig. 9.2 Large plaque parapsoriasis. A Large, variably erythematous patches in the bathing trunk region is a classic presentation. **B** Retiform parapsoriasis with atrophic, red–brown papules in a net-like pattern. While some authors view large plaque parapsoriasis as an entity distinct from mycosis fungoides (MF) or as a potential precursor of MF, many within the field of cutaneous lymphoma consider it to be an early stage of MF.

eFig. 9.3 Chronic form of pityriasis lichenoides (PLC). Multiple, dull red–brown papules, some of which have scale.

eFig. 9.4 Pityriasis lichenoides. Some patients have lesions characteristic of both PLEVA and PLC. *Courtesy Kalman Watsky, MD*.

Downloaded for Anonymous User (n/a) at Egyptian Knowledge Bank from ClinicalKey.com by Elsevier on March 10, 2024. For personal use only. No other uses without permission. Copyright ©2024. Elsevier Inc. All rights reserved.

eFig. 9.5 Pityriasis lichenoides. An admixture of crusted and scaly papules characteristic of PLEVA and PLC, respectively, are seen. *Courtesy Antonio Torrelo, MD.*

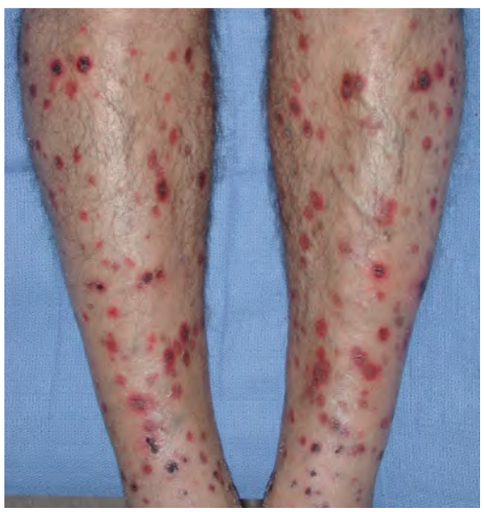

eFig. 9.6 Acute form of pityriasis lichenoides (PLEVA). Widespread erythematous papules, some of which have crusts while others have an ulcerative component.

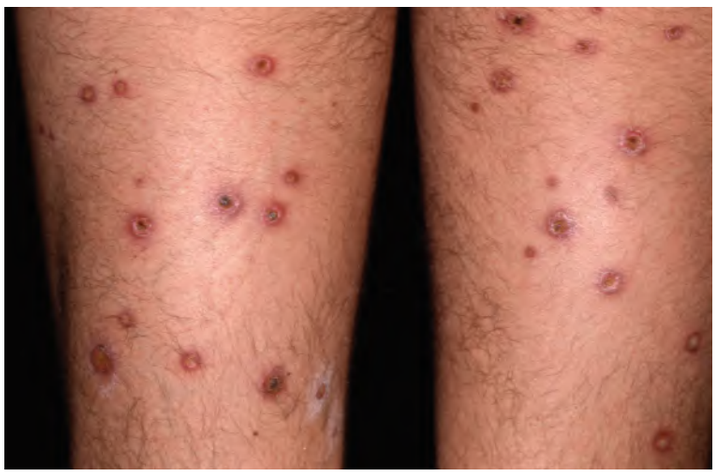

eFig. 9.7 Ulceronecrotic pityriasis lichenoides et varioliformis acuta (PLEVA). Widespread rather monomorphous ulcerations. *Courtesy Lorenzo Cerroni, MD.*

eFig. 9.8 Chronic form of pityriasis lichenoides (PLC). Numerous red–brown papules and hypopigmented macules with variable scaling. *Courtesy Julie V. Schaffer, MD.*

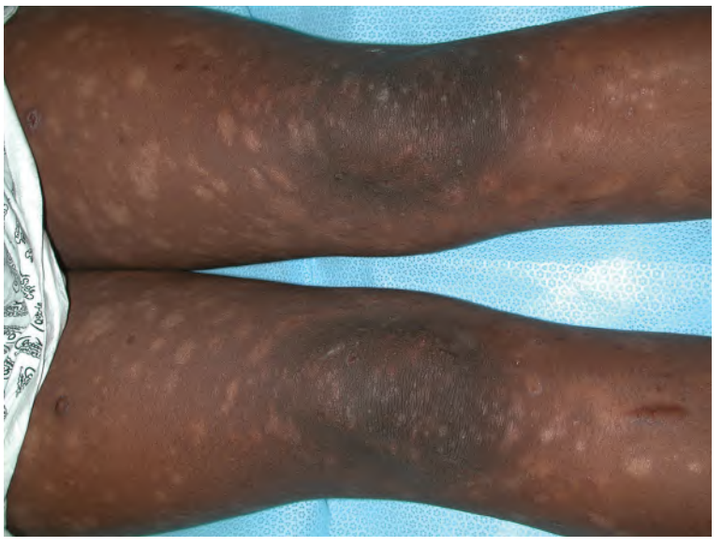

eFig. 9.9 Chronic form of pityriasis lichenoides (PLC) presenting with hypopigmentation. This is more common in darker skin phototypes.

Downloaded for Anonymous User (n/a) at Egyptian Knowledge Bank from ClinicalKey.com by Elsevier on March 10, 2024. For personal use only. No other uses without permission. Copyright ©2024. Elsevier Inc. All rights reserved.

eFig. 9.10 Pityriasis rubra pilaris. Orange–red keratotic follicular papules. *Courtesy Luis Requena, MD.*

eFig. 9.12 Pityriasis rubra pilaris. Well-demarcated, confluent orange–red plaques with scattered follicular papules within areas of sparing.

eFig. 9.11 Pityriasis rubra pilaris. Striking symmetric islands of sparing on the flanks. Follicular papules are present at the periphery of the diffuse erythema. *Used with permission of the Mayo Foundation for Medical Education and Research.*

eFig. 9.13 Pityriasis rubra pilaris. The orange–red color of the skin, including that of the palms, aids in the clinical diagnosis; note the waxy appearance of the keratoderma. *Courtesy Irwin Braverman, MD.*

eFig. 9.14 Pityriasis rubra pilaris-like presentation in Wong variant of juvenile dermatomyositis. *Courtesy Antonio Torrelo, MD.*

Downloaded for Anonymous User (n/a) at Egyptian Knowledge Bank from ClinicalKey.com by Elsevier on March 10, 2024. For personal use only. No other uses without permission. Copyright ©2024. Elsevier Inc. All rights reserved.

eFig. 9.15 Pityriasis rubra pilaris. A, B Erythroderma with hyperkeratosis of the knees. **C** Palmar erythema and scaling with fissures. *Courtesy Jeffrey P. Callen, MD.*

eFig. 9.16 Pityriasis rosea. There is confluence of the lesions on the mid anterior trunk; note the scale in several lesions. *Courtesy Antonio Torrelo, MD.*

eFig. 9.17 Pityriasis rosea. Papules of varying size and small plaques, some of which are oval in shape. The patient was 59 years old. *Courtesy Jeffrey P. Callen, MD.*

eFig. 9.18 Pityriasis rosea. Both oval and round plaques can be seen as well as central fine scale or a collarette of scale. *Courtesy Julie V. Schaffer, MD.*

eFig. 9.19 Pityriasis rosea in more darkly pigmented skin. Note the associated hyperpigmentation.

eFig. 9.20 Pityriasis rosea. Two herald patches are seen. *Courtesy Kalman Watsky, MD.*

Downloaded for Anonymous User (n/a) at Egyptian Knowledge Bank from ClinicalKey.com by Elsevier on March 10, 2024. For personal use only. No other uses without permission. Copyright ©2024. Elsevier Inc. All rights reserved.

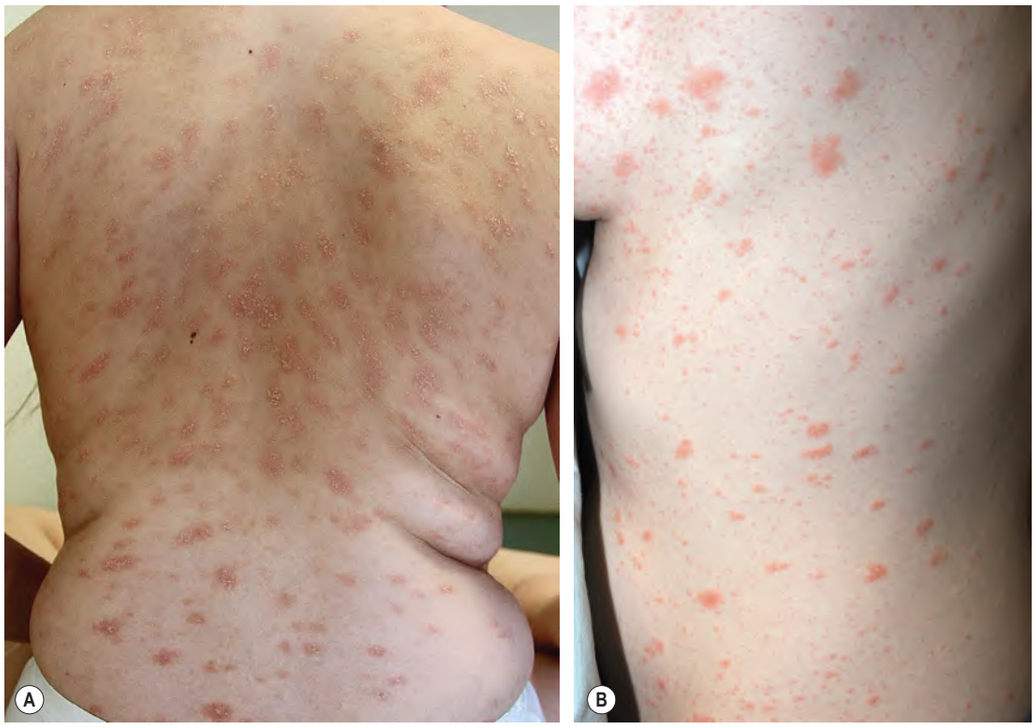

eFig. 9.21 Pityriasis rosea. A Multiple papulosquamous lesions on the back whose long axes follow the skin tension lines, leading to a "fir tree" or "Christmas tree" pattern. **B** On the flank, mixture of classic lesions with tiny pink papules. *B, Courtesy Kalman Watsky, MD*.

eFig. 9.22 Inverse pityriasis rosea. Circular and oval-shaped plaques; some have central white scale while others have a more peripheral collarette of scale. *Courtesy Kalman Watsky, MD*

eFig. 9.23 Pityriasis rosea. Several of the dull pink plaques have a collarette of white scale. *Courtesy Jean L. Bolognia, MD*.

eFig. 9.24 Inverse pityriasis rosea. Oval plaques with peripheral scale on the central buttocks. *Used with permission of the Mayo Foundation for Medical Education and Research*.

Downloaded for Anonymous User (n/a) at Egyptian Knowledge Bank from ClinicalKey.com by Elsevier on March 10, 2024. For personal use only. No other uses without permission. Copyright ©2024. Elsevier Inc. All rights reserved.

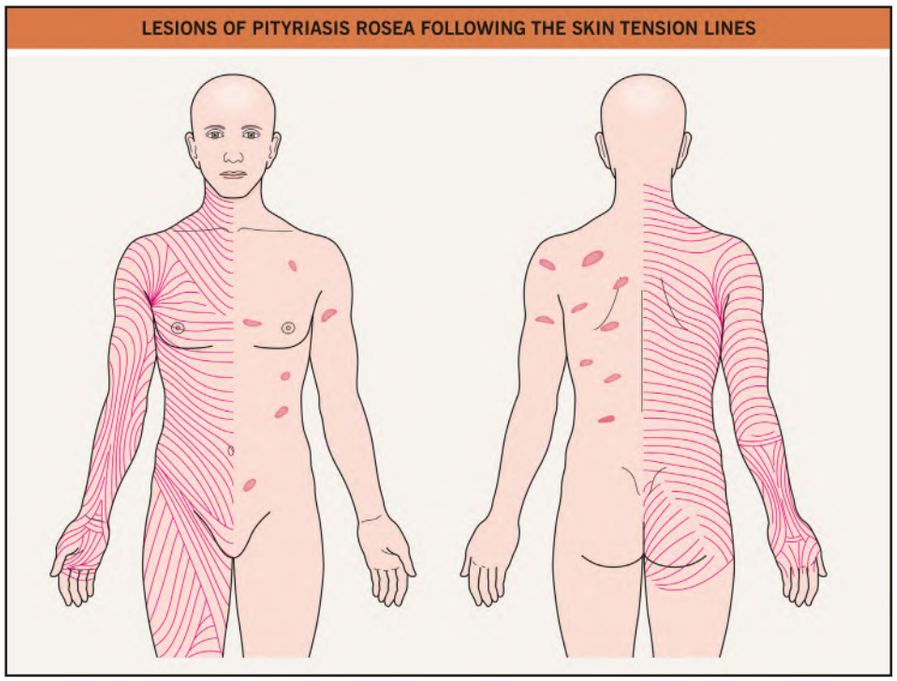

eFig. 9.25 Lesions of pityriasis rosea following the skin tension lines. These lines are often referred to as Langer cleavage lines. The long axis of the individual lesions aligns with these lines.

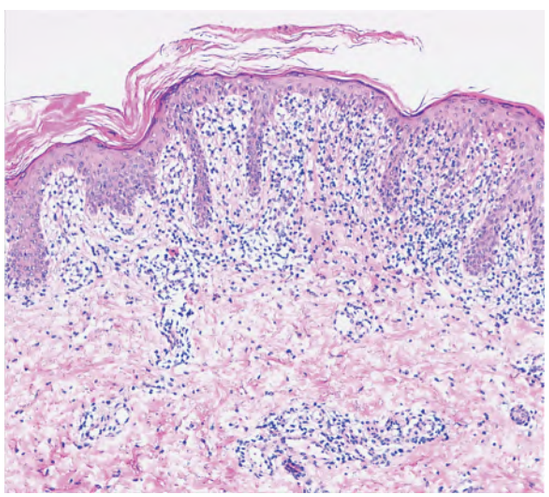

eFig. 9.26 Lichenoid interface dermatitis with exocytosis of lymphocytes and focal parakeratosis.

eFig. 9.27 Pityriasis rotunda. Circular, well demarcated, thin hyperpigmented plaques with scale. *Courtesy John Hughes, MD.*

Downloaded for Anonymous User (n/a) at Egyptian Knowledge Bank from ClinicalKey.com by Elsevier on March 10, 2024. For personal use only. No other uses without permission. Copyright ©2024. Elsevier Inc. All rights reserved.

eFig. 9.28 Granular parakeratosis. Brownish-red papules with coalescence into a keratotic plaque in the axilla. *Courtesy David Mehregan, MD.*

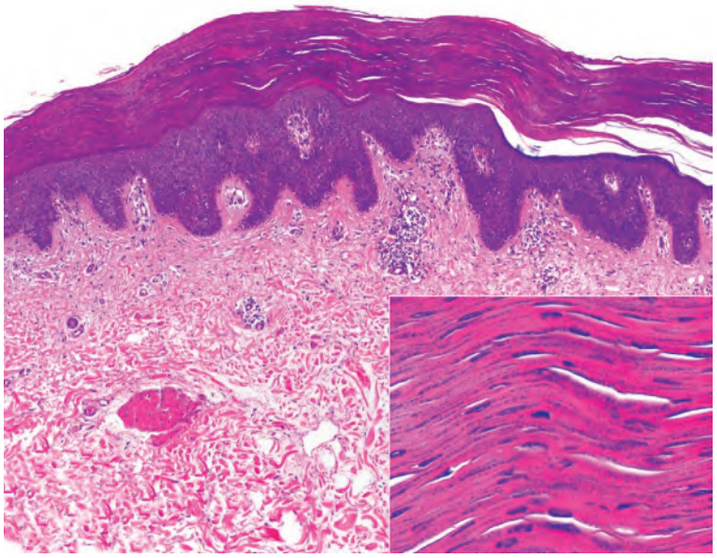

eFig. 9.29 Axillary granular parakeratosis – histopathology. Marked, compact parakeratosis with small bluish granules within the stratum corneum representing keratohyaline granules (inset). *Courtesy Luis Requena, MD.*

Downloaded for Anonymous User (n/a) at Egyptian Knowledge Bank from ClinicalKey.com by Elsevier on March 10, 2024. For personal use only. No other uses without permission. Copyright ©2024. Elsevier Inc. All rights reserved.